

PATIENT

Heisenberg Trovato

SPECIES

Feline

BREED

Russian Blue

SEX

MN

AGE

3½ years

WEIGHT

12.7 #

INTERPRETED BY

Remo Lobetti, BVSc,
MMedVet (Med), PhD,
Dipl. ECVIM

IMAGING PERFORMED BY

Lara Wiseman, DVM

HOSPITAL NAME

Boca Midtowne Animal
Hospital

REFERRING VET

Dr Boazman

INVOICE

303447

DATE

9/30/22

PRESENTING CLINICAL SIGNS

History: Urinary issues past 48 hours – treated with Convenia and Buprenex at ER.

Physical Examination: N/A.

Urinalysis: N/A.

CBC: N/A.

Serum Biochemistry: N/A.

Radiographic Findings: N/A.

ULTRASONOGRAPHIC EXAMINATION OF THE ABDOMEN

Urinary System

Full urinary bladder with a thickened and irregular appearance of the wall, especially the apex. Moderate amount of floating and adherent hyperechogenic sediment. No uroliths evident. Cystocentesis performed.

Normal trigone area, proximal urethra (0.2 cm), and iliac blood vessels.

Normal iliac lymph nodes. Ureters not visualized.

Normal renal size (left 3.6 cm, right 4.1 cm), echogenic appearance, cortico-medullary differentiation, pelvis, and capsule.

Reproductive System

N/A.

Adrenal Glands

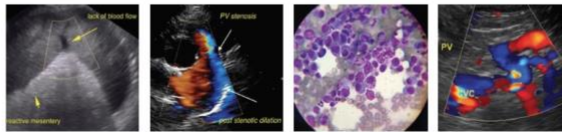
Normal shape, echogenic appearance, position, and size. Left 0.39 cm, right 0.36 cm.

Spleen

Normal size (0.8 cm) and echogenic appearance. Smooth homogenous parenchyma, regular curvilinear capsule, and normal vasculature. No evidence of inflammatory, neoplastic, infarction, or infiltrative changes noted.

Liver

Normal size, echogenic appearance, portal markings, and regular curvilinear capsule. No nodules or masses evident. Full gall bladder containing normal anechoic bile. Normal thickness and echogenic appearance of the gall bladder wall. Normal bile duct (0.1 cm).



PATIENT

Heisenberg Trovato

SPECIES

Feline

BREED

Russian Blue

SEX

MN

AGE

3½ years

WEIGHT

12.7 #

INTERPRETED BY

Remo Lobetti, BVSc,
MMedVet (Med), PhD,
Dipl. ECVIM

IMAGING PERFORMED BY

Lara Wiseman, DVM

HOSPITAL NAME

Boca Midtowne Animal
Hospital

REFERRING VET

Dr Boazman

INVOICE

303447

DATE

9/30/22

Gastrointestinal

Normal appearance of the gastro-esophageal junction, stomach, duodenum, small intestine, ileo-cecal junction, and colon with no loss of layering, normal wall thickness (stomach 0.19 cm, duodenum 0.26 cm, jejunum 0.26 cm) and peristaltic activity, and no distension of the lumen.

Pancreas

Normal size (right 0.7 cm) and echogenic appearance. Regular capsule. Normal echogenic appearance of the mesentery and fat surrounding the pancreas.

Free Abdomen

No mesenteric lymphadenomegaly.
No ascites.

ULTRASONOGRAPHIC FINDINGS

Primary findings:

- Cystitis

Secondary findings:

- None.

INTERPRETATION OF THE FINDINGS & FURTHER RECOMMENDATIONS

Etiologies for the cystitis would be bacterial cystitis, sterile cystitis, and severe crystalluria.

Further assessment would be urinalysis and urine culture.

Specific therapy would be dependent on an etiological diagnosis.



PATIENT

Heisenberg Trovato

SPECIES

Feline

BREED

Russian Blue

SEX

MN

AGE

3½ years

WEIGHT

12.7 #

INTERPRETED BY

Remo Lobetti, BVSc,
 MMedVet (Med), PhD,
 Dipl. ECVIM

IMAGING PERFORMED BY

Lara Wiseman, DVM

HOSPITAL NAME

Boca Midtowne Animal
 Hospital

REFERRING VET

Dr Boazman

INVOICE

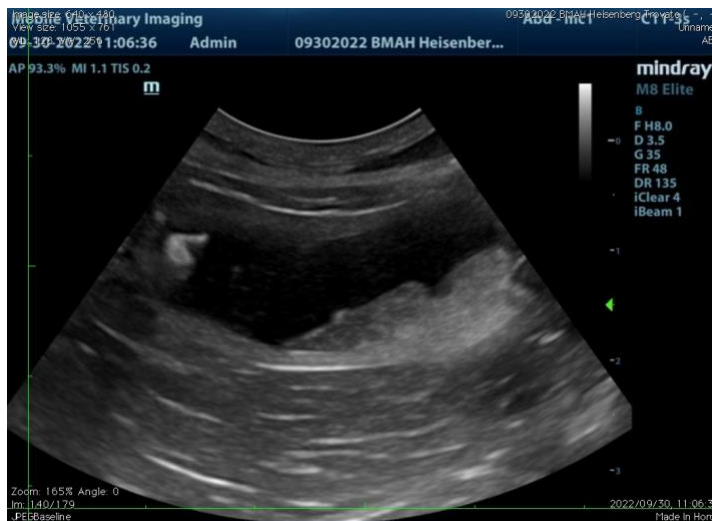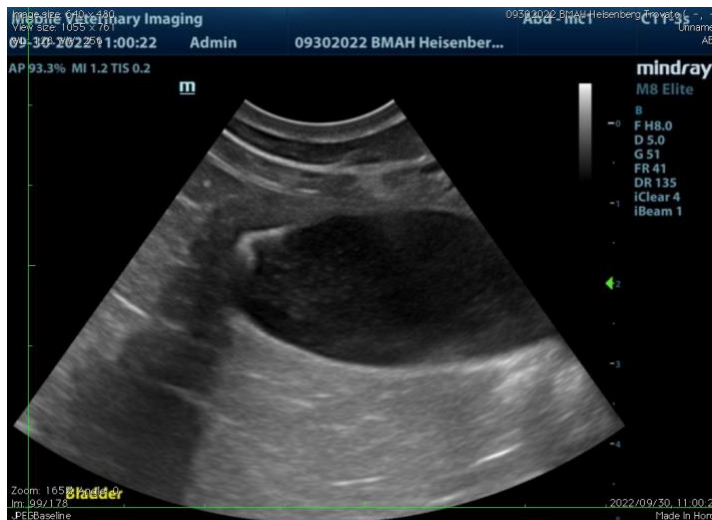303447

DATE

9/30/22

IMAGES

Urinary bladder



The information and recommendations provided are based on the images presented by the referring veterinarian. No evaluation can be communicated regarding pathology that was not visible in the image/video clips provided.

Thank you for this referral. If the clinical or image interpretation does not parallel your findings or if I can be of any further assistance please contact me.

Remo Lobetti, BVSc, MMedVet (Med), PhD, Dipl. ECVIM (Internal Medicine)
 rlobetti@mweb.co.za